


Clinical Advantages of Quantitative Electroencephalogram (QEEG)–Electrical Neuroimaging Application in General Neurology Practice

Clinical EEG and Neuroscience
44(4) 273-285
© EEG and Clinical Neuroscience
Society (ECNS) 2013
Reprints and permission:
sagepub.com/journalsPermissions.nav
DOI: 10.1177/1550059412475291
eeg.sagepub.com


J. Lucas Koberda¹, Andrew Moses^{1,2}, Paula Koberda^{1,2}, and
Laura Koberda^{1,2}

Abstract

QEEG-electrical neuroimaging has been underutilized in general neurology practice for uncertain reasons. Recent advances in computer technology have made this electrophysiological testing relatively inexpensive. Therefore, this study was conducted to evaluate the clinical usefulness of QEEG/electrical neuroimaging in neurological practice. Over the period of approximately 6 months, 100 consecutive QEEG recordings were analyzed for potential clinical benefits. The patients who completed QEEG were divided into 5 groups based on their initial clinical presentation. The main groups included patients with seizures, headaches, post-concussion syndrome, cognitive problems, and behavioral dysfunctions. Subsequently, cases were reviewed and a decision was made as to whether QEEG analysis contributed to the diagnosis and/or furthered patient's treatment. Selected and representative cases from each group are presented in more detail, including electrical neuroimaging with additional low-resolution electromagnetic tomography analysis or using computerized cognitive testing. Statistical analysis showed that QEEG analysis contributed to 95% of neurological cases, which indicates great potential for wider application of this modality in general neurology. Many patients also began neurotherapy, depending on the patient's desire to be involved in this treatment modality.

Keywords

QEEG, electrical neuroimaging, neurology, neurofeedback

Received June 23, 2012; revised October 2012; accepted December 28, 2012

Introduction

QEEG was introduced in the 1970s as an experimental testing modality of brain-wave recordings; however, with time QEEG has become more widely used for neurological evaluation of epilepsy and behavioral problems in psychiatry. Due to remarkable advancement in computer technology and low cost of computers, QEEG testing became affordable for any medical practice.

The QEEG is based on mathematical processing of standard electroencephalography (EEG), which condenses the EEG data to a single page color-coded summary. This gives a neurologist unprecedented ability to look at summarized EEG information, which was not previously possible with regular EEG. Unfortunately, most US neurology residency training programs do not offer QEEG/electrical neuroimaging¹ training in their curriculum, which results in very limited application of this modality in general neurology practice. Review of the previous literature revealed no consensus among US neurologists, as to whether QEEG should be used in general neurology practice.²⁻⁵ Therefore, I

analyzed patients from my general neurology clinic. One hundred QEEG cases were reviewed, with special attention given to whether the electrical neuroimaging contributed clinically to diagnosis, decision making, or treatment.

Materials and Methods

We analyzed 100 consecutive cases of patients, with various neurological problems, who completed QEEG in our general neurology clinic, at Florida State University, College of Medicine, Tallahassee, Florida. The patients were reviewed from

¹ Tallahassee NeuroBalance Center, Tallahassee, FL, USA

² Florida State University, Tallahassee, FL, USA

Corresponding Author:

J. Lucas Koberda, Tallahassee NeuroBalance Center, PO Box 13554, Tallahassee, FL 32317, USA.

Email: JLKoberda@yahoo.com

Full-color figures are available online at <http://eeg.sagepub.com>

Table 1. Analysis of Group 1 Patients With Working Diagnosis of Possible Epilepsy, Seizure, Syncope, CVA, or MS.

Patient's number	Clinical Presentation	QEEG findings	Clinical implication or relevance
N-18	Seizure, MS, syncope, CVA	Focal sharp/wave discharges, focal increase in delta or theta power or LORETA localization	13 QEEGs were confirmed as a clinically relevant (72%) Mostly syncope cases showed no major abnormalities

Abbreviations: CVA, cerebrovascular accident; LORETA, low-resolution electromagnetic tomography analysis; QEEG, quantitative electroencephalogram; MS, multiple sclerosis.

Table 2. Analysis of Group 2 Patients With Diagnosis of Intractable HA and Frequently Overlapping Anxiety.

Patient's number	Clinical presentation	QEEG findings	Clinical implication or relevance
N-13	HA overlapping anxiety	Frontal or occipital increase in beta power	All 13 QEEGs were confirmed as clinically relevant (typical beta phenotype)

Abbreviations: HA, headache; QEEG, quantitative electroencephalogram.

Table 3. Group 3 Patients Diagnosed With Probable Post-Concussion Syndrome (PCS) Analyzed by Traumatic Brain Injury Discriminant Analysis (TBI-DA).

Patient's number	Clinical presentation	QEEG findings and other testing	Clinical implication or relevance
N-33	PCS	Positive or negative TBI-DA, frontal-central increase in delta or theta power, increase in frontal beta power, positive LORETA, and/or neurocognitive testing abnormalities	All 33 cases were confirmed as clinically relevant—confirmation of diagnosis and/or localized cortical dysfunction

Abbreviations: LORETA, low-resolution electromagnetic tomography analysis; QEEG, quantitative electroencephalogram.

Table 4. Analysis of Group 4 Patients Complaining of Progressive Memory and Cognitive Problems.

Patient's number	Clinical presentation	QEEG findings	Clinical implication or relevance
N-12	Cognitive dysfunction	Frontotemporal or global slowing (increase in delta or theta power)	All QEEGs were confirmed as clinically relevant—confirmation of likely organic dysfunction

Abbreviation: QEEG, quantitative electroencephalogram.

Table 5. Analysis of Group 5 Patients Complaining of Behavioral Problems Including Depression, ADD, Anxiety, and Autistic disorder.

Patient's number	Clinical presentation	QEEG findings and other testing	Clinical implication or relevance
N-24	ADD, AS, depression, anxiety, autism	Increase in frontocentral theta and theta/beta ratio, alpha asymmetry, increase in frontal or occipital beta power, positive LD-DA, and abnormalities in SPECT	All 24 QEEGs were found clinically relevant—typical phenotype

Abbreviations: ADD, attention deficit disorder, AS, Asperger syndrome; LD-DA, learning disability discriminant analysis; QEEG, quantitative electroencephalogram; SPECT, single photon emission computed tomography.

September 2010 to February 2011. One hundred consecutive patients, who completed QEEG studies in our general neurology clinic, were divided into 5 groups based on their initial clinical presentation (see Tables 1-5). One representative case from each group was selected and presented in more detail. Statistical analysis for different groups of patients is presented as the percentage of patients where QEEG was clinically useful in diagnosis and evaluation. The patients' workup depended on the presenting problem and, frequently in addition, the general neurological examination included brain imaging (magnetic resonance imaging [MRI] or computed tomography) and/or commercially

available computerized neurocognitive testing⁶ (NeuroTrax Corp, Mindstreams assessment, Bellaire, Texas). NeuroTrax Corp neurocognitive testing is a computerized neuropsychological assessment where the patient is compared to age- and education-matched healthy controls where mean = 100 with 1 standard deviation = 15. The QEEG analysis was completed using commercially available Neuroguide⁷ (St. Petersburg, Florida) software and previously recorded 19 channels digital EEG.

Approximately, 3 to 5 minutes of artifact-free closed eyes EEG segments were selected and subjected to further QEEG analysis. Traumatic brain injury discriminant analysis (TBI-

DA)⁸ was used for eligible patients aged 5-18 years, who sustained prior head injury and learning disability discriminant analysis⁹ for eligible patients aged 5 to 18 years. The Low-resolution electromagnetic tomography analysis (LORETA)^{10,11} was also used for better cortical localization of the clinical problem.^{10,11}

Results

Tables 1-5 show the summary of patients assigned to each of the groups. Table 1 contains data of 18 patients with an initial working diagnosis of seizure versus syncope, as well as the data of patients with potential stroke or multiple sclerosis. Thirteen QEEGs were clinically significant. Table 2 includes data of 13 patients with chronic headaches and probable overlapping anxiety. All 13 QEEGs were found to be clinically contributory. Table 3 contains data of 33 patients who sustained head injury and diagnosed with possible post-concussion syndrome (PCS) based on their complaints and history of accidents. All 33 QEEGs were found to contribute to clinical diagnosis and potential treatment. Table 4 includes data of 12 patients with symptoms of memory and cognitive problems suggesting the possibility of dementia. All 12 QEEGs were found to be clinically contributory, where confirmation of EEG slowing was indicative of likely organic etiology. Table 5 shows data of 24 patients presenting mostly with behavioral problems, including depression, anxiety, or attention deficit problems. Also, patients having autistic spectrum disorder were included in this group. All 24 QEEGs were found to be contributory to diagnosis and/or treatment.

When all tables were summarized, 95% of 100 consecutive QEEG analyses were found to be clinically contributory. For each group, 1 representative case is presented in detail. Patient R.R. was a 52-year-old female with a history of intractable epilepsy. Multiple standard digital EEGs completed in different hospitals were reported as normal, as well as brain imaging with 3 Tesla MRI and epilepsy protocol. Subsequent QEEG and LORETA showed evidence of right temporal dysfunction (Figure 1). Additional video-telemetry, completed in university settings, confirmed the diagnosis of right temporal epilepsy (patient developed seizures during EEG video observation originating from the right temporal location).

Patient I.A. was a 24-year-old female with a history of intractable headaches. Electrical neuroimaging analysis showed marked increase in frontal β power (Figure 2), confirming typical QEEG presentation of individuals with chronic headache.

Another patient is a 20-year-old female student who, while riding her scooter, was hit by a car and sustained head injury with probable loss of the consciousness. Subsequently, she complained of memory and concentration problems, headaches and insomnia, and was diagnosed with PCS. Neurocognitive testing with Neuro-Trax (Figure 3) revealed a global cognitive score of 95 (below average cognitive performance), with most deficient memory testing—60.2 (below 2 standard deviation from the average), as well as reduced attention—92.7. Additional electrical neuroimaging, and LORETA analysis, showed increased bilateral temporal

θ power (Figure 4), indicative of potential temporal dysfunction consistent with the patient's clinical presentation. The TBI-DA was also positive for TBI.

Another example is patient D.F., an 81-year-old male with a history of progressive memory and cognitive problems. Both QEEG and LORETA analyses showed increase in θ power in bilateral temporal regions confirming a diagnosis of most likely organic neurodegenerative process (Figure 4).

The neurobehavioral group was represented by patient K.P., who was a 17-year-old student with long-standing history of attention deficit disorder (ADD) and Asperger syndrome. Electrical neuroimaging revealed findings typical for ADD phenotypic presentation, with frontal increase in θ power as well as elevated θ/β ratio. Additional learning disability discriminant analysis also confirmed evidence of learning dysfunction (Figure 5). Subsequently, this patient was given neurofeedback treatment, since he had no desire to take stimulant medication.

Discussion

This report contains analysis of 100 consecutive patients who underwent QEEG in our neurology practice, and to our knowledge, it constitutes the first article to address the usefulness of this testing in general neurological practice. Prior literature mostly consists of single or multiple case studies of selected neurological¹² or psychiatric conditions.^{13,14} Also, application of QEEG in chronic pain, including fibromyalgia¹⁵ as well as headaches, was previously reported.¹²

From a neurological point of view, current underutilization of QEEG impedes progress in diagnosis. QEEG is a relatively inexpensive technology, with excellent temporal resolution and reasonable spatial resolution.¹⁶ In addition, most neurologists are very familiar with raw EEG analysis which is essential for good QEEG interpretation. Based on the above data, most patients analyzed in our practice benefited from QEEG/LORETA, except for syncope patients. This finding is not unexpected since syncope patients are mostly cardiovascular, where no major focal brain abnormalities are expected. However, during initial clinical evaluation, those patients are sometimes difficult to separate from seizure or epilepsy cases.

QEEG analysis of patients with chronic headache (Table 2) confirms a prior report indicating increase in β power in frontal and/or occipital locations.¹² These patients frequently had coexisting anxiety, contributing to elevated β band expression.¹⁷

QEEG analysis of patients with PCS showed that most had a marked increase in frontotemporal and central θ power in addition to positive TBI-DA. A smaller group of patients had an increase in frontocentral β power. Overall, high sensitivity of PCS detection using QEEG was also previously reported.¹⁸ The potential usefulness of QEEG to quantify TBI in the emergency department was suggested by other authors.¹⁹ Individuals with negative TBI-DA may be in need of additional neuropsychological testing in order to validate, or rule out, the diagnosis of PCS.

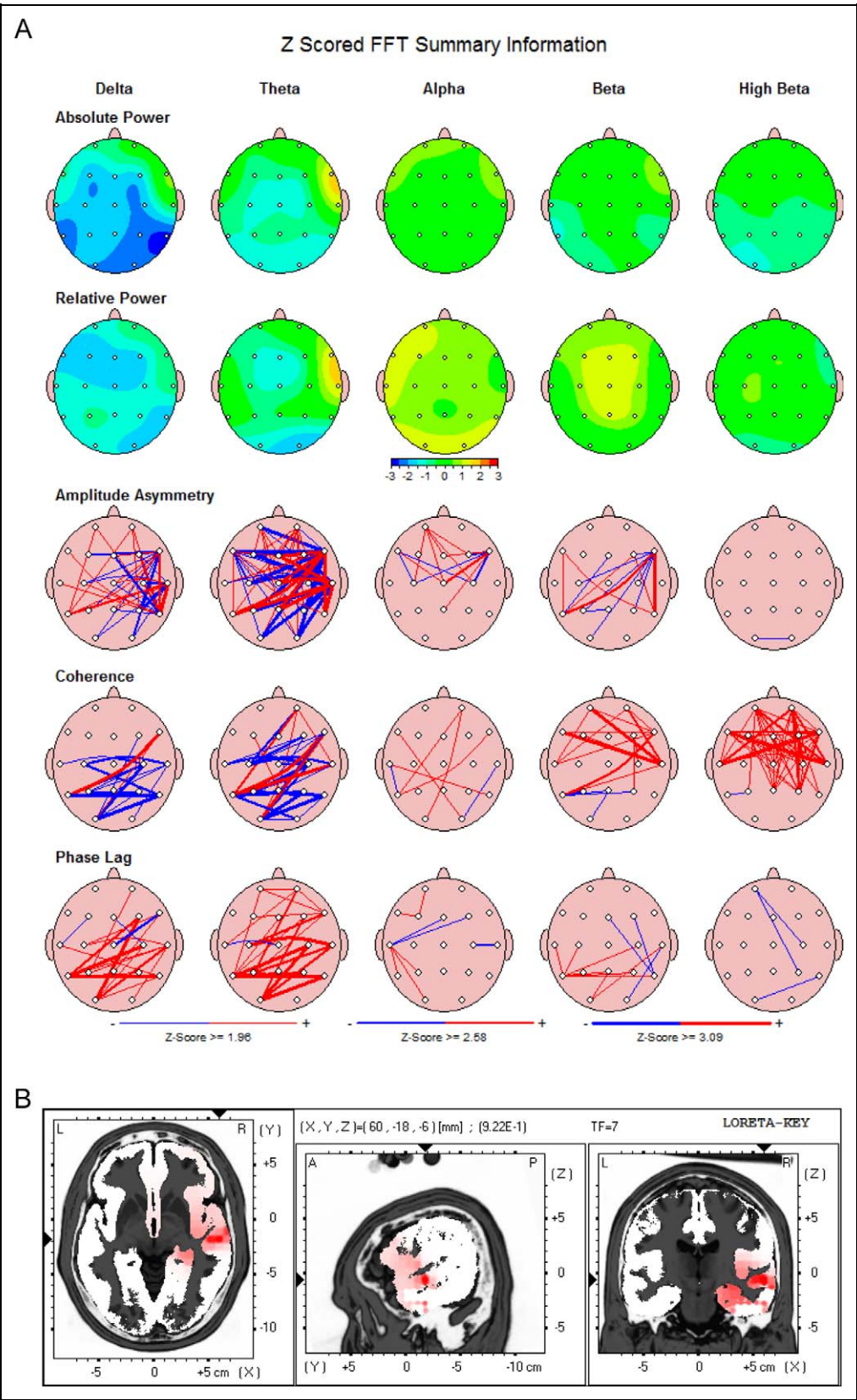


Figure 1. A, Patient with epilepsy had right temporal increase in θ power; second picture from the upper left shows increase in the right temporal θ power, yellow color indicates that this area is between 1 and 2 standard deviations (SDs) from the norm. B, Low-resolution electromagnetic tomography analysis (LORETA) for patient with epilepsy shows increase in θ activity in the right temporal area (increased activity is shown in red).

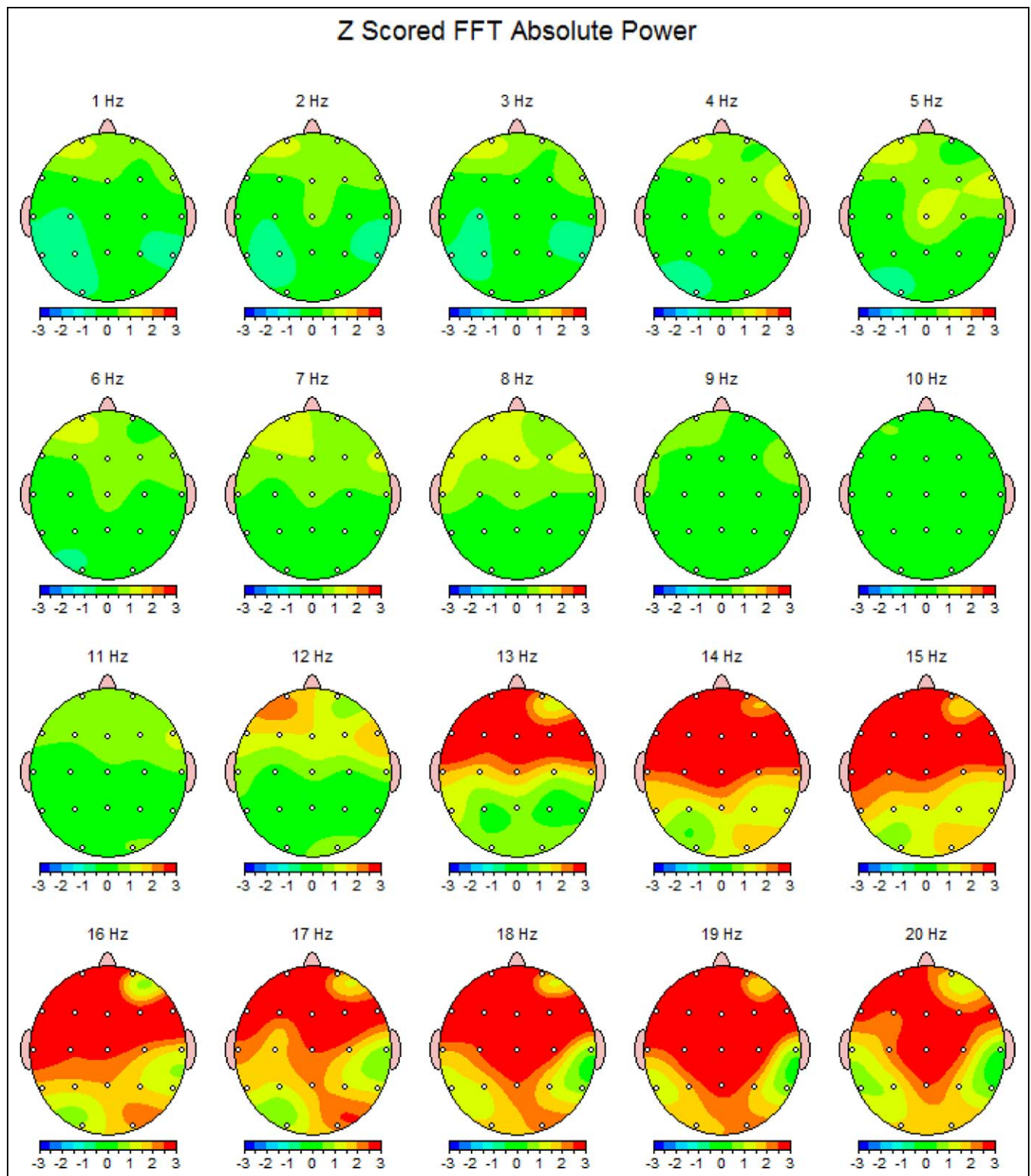


Figure 2. Increased absolute frontal β power in patient with chronic headache (HA); frontal red area (between 2 and 3 standard deviation [SD]) in pictures shows 13 to 20 Hz frequency (green color shows areas between 0 and 1 SD; yellow between 1 and 2 SD).

QEEG findings of patients with memory and cognitive problems (Table 4) revealed marked increase in θ and sometimes even δ power, confirming likely organic etiology of their underlying condition. Patients with major dementia may be having global increase in

θ or even δ power, and patients with milder cognitive problems may have just frontotemporal θ power elevation. These findings are in agreement with prior reports indicating the clinical usefulness of QEEG in detecting demented individuals.^{16,20}

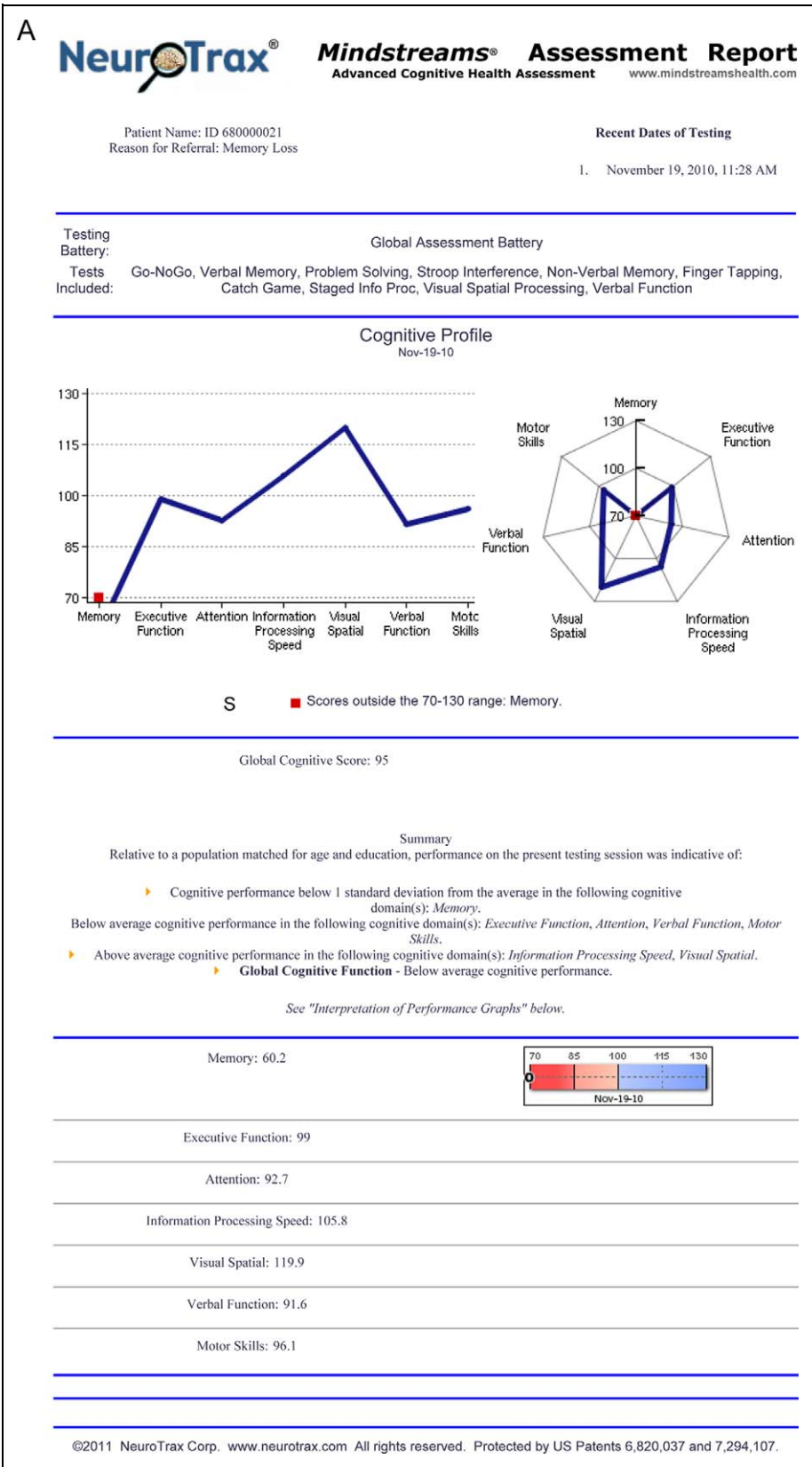


Figure 3. Continued

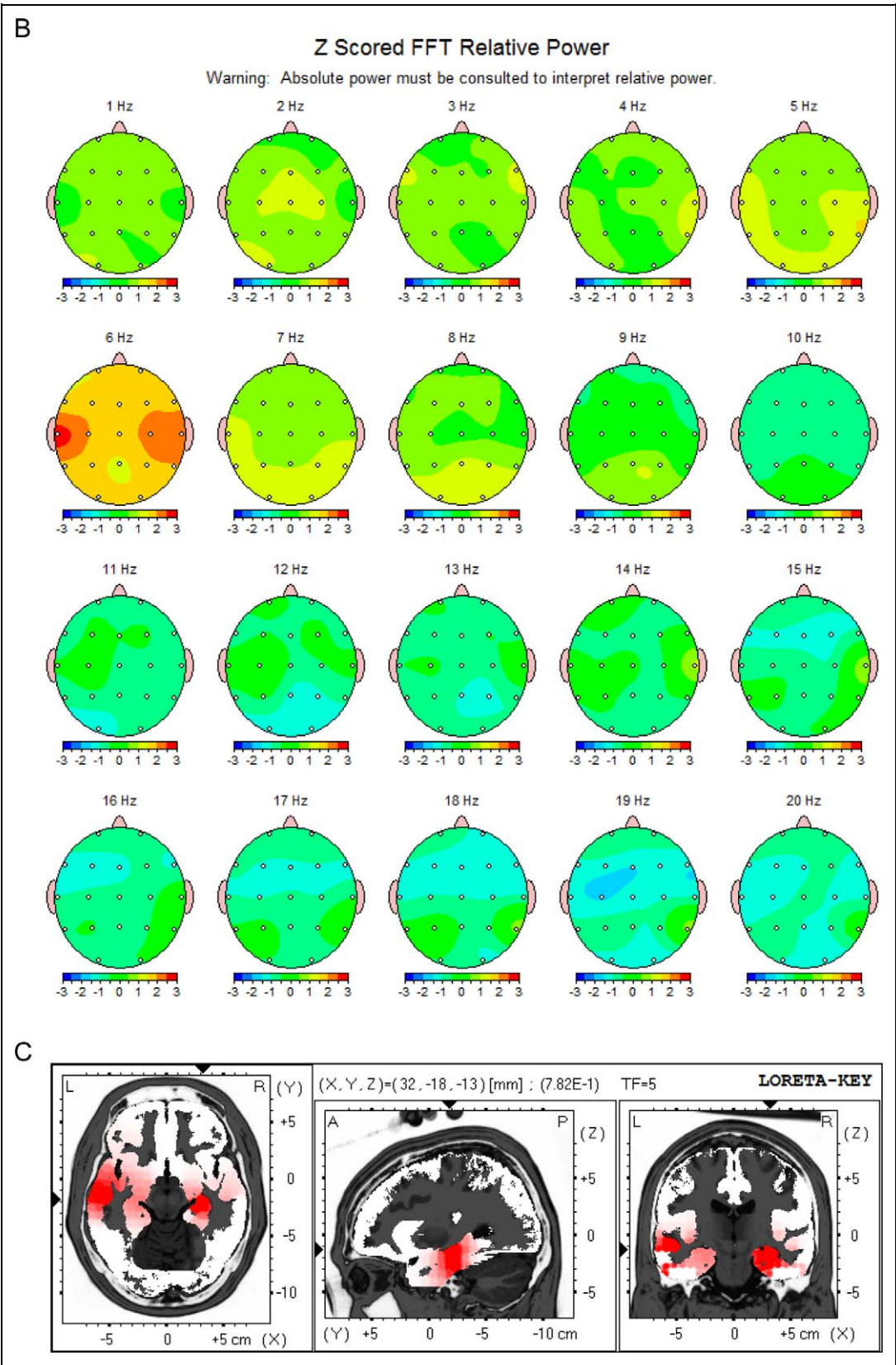


Figure 3. Continued

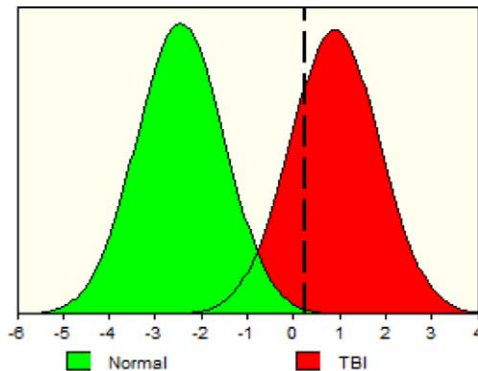
D

Traumatic Brain Injury Discriminant Analysis*

TBI DISCRIMINANT SCORE = 0.21

TBI PROBABILITY INDEX = 97.5%

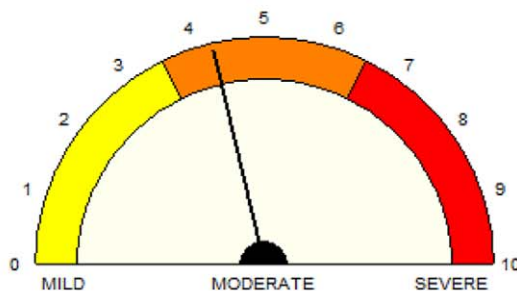
The TBI Probability Index is the subject's probability of membership in the mild traumatic brain injury population. (see Thatcher et al, EEG and Clin. Neurophysiol., 73: 93-106, 1989.)



			RAW	Z
FP1-F3	COH	Theta	84.13	0.61
T3-T5	COH	Beta	51.66	0.19
C3-P3	COH	Beta	83.73	1.49
FP2-F4	PHA	Beta	0.07	-1.24
F3-F4	PHA	Beta	0.12	-1.29
F4-T6	AMP	Alpha	23.18	1.63
F8-T6	AMP	Alpha	-46.37	1.54
F4-T6	AMP	Beta	34.84	1.05
F8-T6	AMP	Beta	3.02	1.61
F3-O1	AMP	Alpha	-75.72	0.35
F4-O2	AMP	Alpha	-107.45	-0.19
F7-O1	AMP	Alpha	120.21	-0.37
F4-O2	AMP	Beta	-30.05	0.25
P3	RP	Alpha	47.26	-0.34
P4	RP	Alpha	53.30	0.03
O1	RP	Alpha	56.27	-0.21
O2	RP	Alpha	62.88	0.17
T4	RP	Alpha	25.91	-0.97
T5	RP	Alpha	43.94	-0.44
T6	RP	Alpha	44.67	-0.58

TBI SEVERITY INDEX = 4.27

This severity score places the patient in the MODERATE range of severity.



			RAW	Z
FP1-C3	COH	Delta	41.80	-0.30
FP1-FP2	COH	Theta	91.02	1.01
O1-F7	COH	Alpha	16.34	-0.82
O2-T6	COH	Alpha	80.11	-0.26
P3-O1	COH	Beta	79.33	0.78
FP1-T3	PHA	Theta	0.30	-1.56
T3-T4	PHA	Theta	38.74	0.52
O1-F7	PHA	Alpha	-37.92	0.42
F7-F8	PHA	Alpha	-1.36	-0.36
T5-T6	PHA	Beta	4.34	0.33
C3-F7	AMP	Delta	-22.82	-2.63
FP2-F4	AMP	Delta	46.28	1.89
C4-F8	AMP	Delta	6.22	-1.58
O1-O2	AMP	Theta	-19.24	-0.74
P3-F7	AMP	Alpha	103.81	-0.73
FP2-P4	AMP	Alpha	-94.90	0.24

The TBI Severity Index is an estimate of the neurological severity of injury. (see Thatcher et al, J. Neuropsychiatry and Clinical Neuroscience, 13(1): 77-87, 2001.)

*Statement of Indications of Use:

The Discriminant Analysis and Severity Index are to be used by experienced and qualified professionals for the post-hoc statistical evaluation of the human electroencephalogram (EEG). The Discriminant Analysis and Severity Index are to be viewed as an adjunct to the evaluation of the patient, and they do not serve as a primary basis for a diagnosis. Warning: Inclusion criteria of a history of traumatic brain injury and greater than 13 years of age must be adhered to.

Figure 3. A, NeuroTrax Corp neurocognitive testing for patient with post-concussion syndrome (PCS; indicating low memory score of 60.2). B, Patient with PCS had increased bilateral temporal (6 Hz) θ power (at 6 Hz frequency bilateral temporal power is in red indicating it is within 2 to 3 standard deviation [SD] from the norm). C, Patient with PCS had increased θ activity in the bilateral temporal location (low-resolution electromagnetic tomography analysis [LORETA]); red color indicates abnormal regions. D, Positive traumatic brain injury discriminant analysis for patient with head injury.

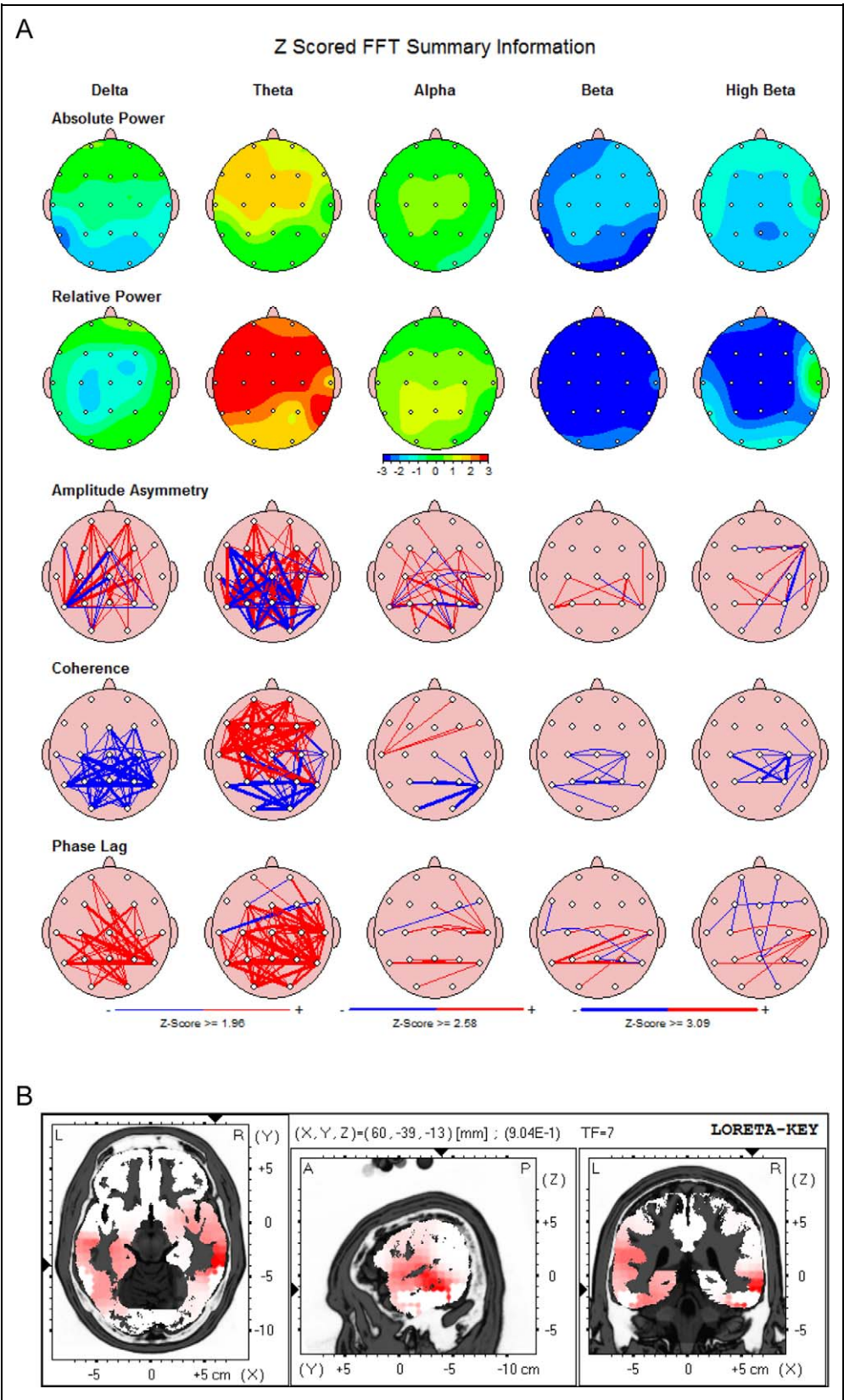


Figure 4. A, Patient with progressive cognitive problems had increased frontotemporal θ power (yellow color is between 1 and 2 standard deviation [SD] in absolute power and red color between 2 and 3 SD in relative power). B, Low-resolution electromagnetic tomography analysis (LORETA) analysis for patient with progressive cognitive problems showed increased bilateral temporal θ activity (shown in red).

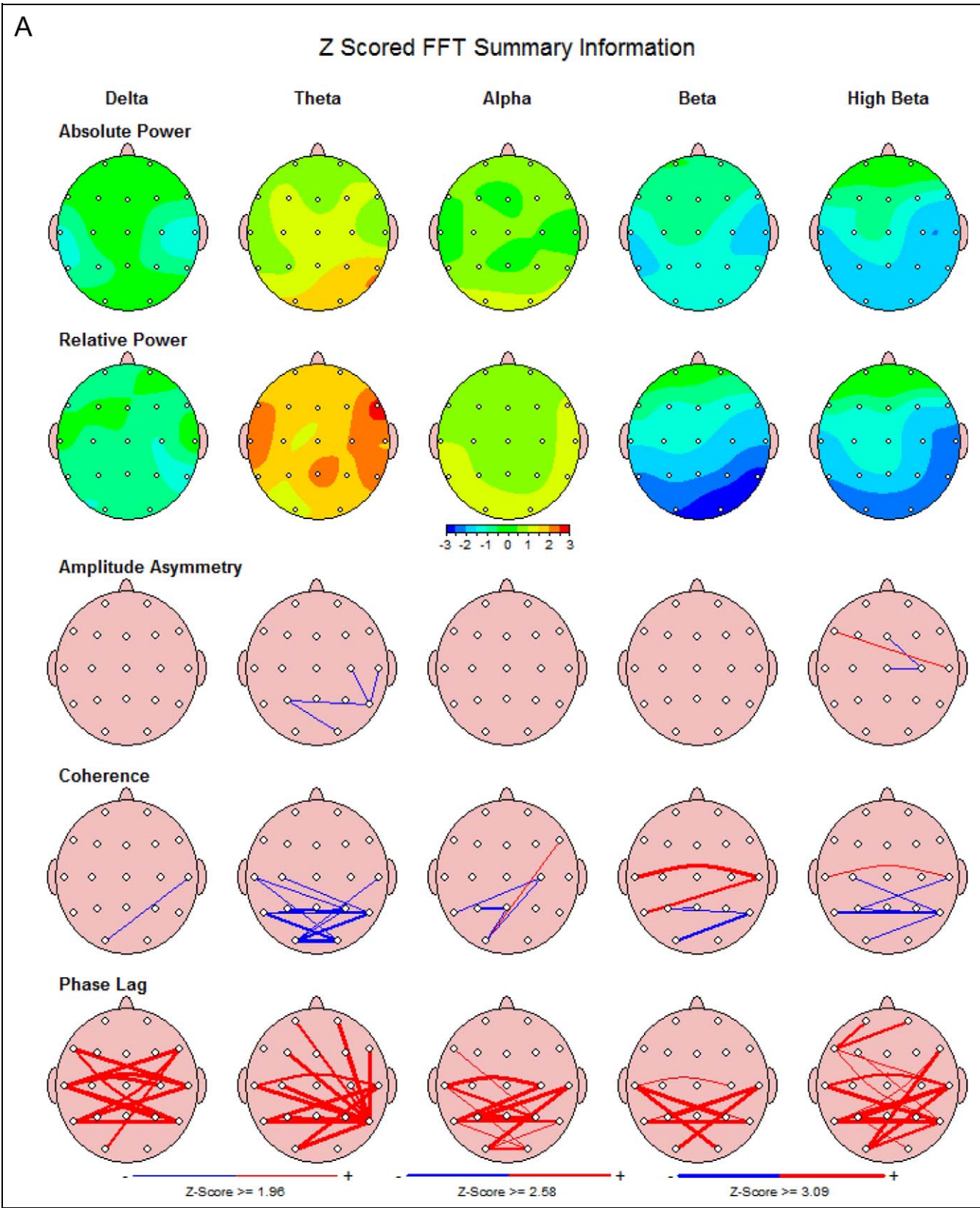


Figure 5. Continued.

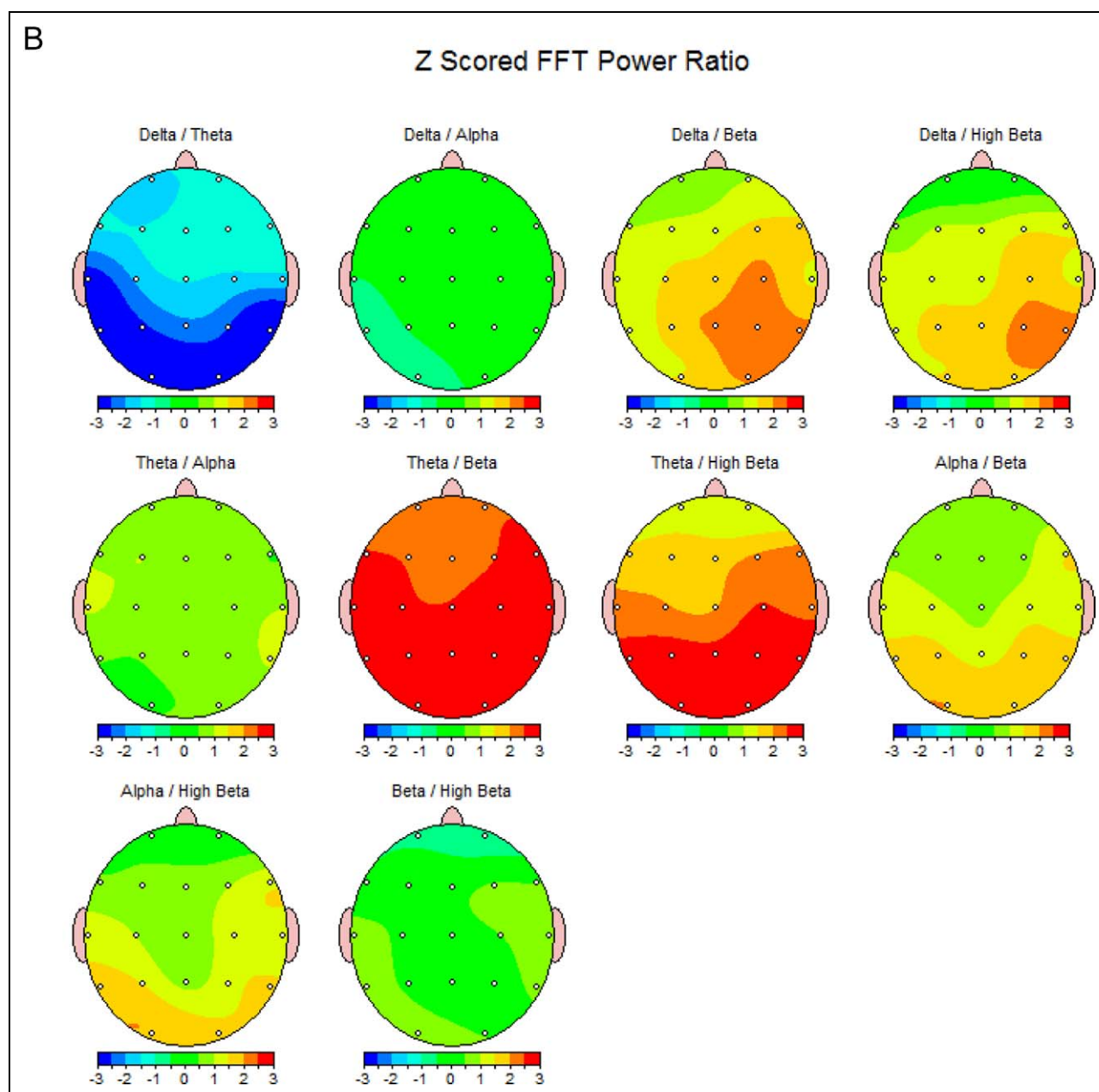


Figure 5. Continued.

Electrical neuroimaging of patients presenting with sometimes clinically distinct behavioral problems, confirmed the usefulness of this technique in behavioral neurology. Previously, other authors have described characteristic QEEG phenotypes for patients with depression, where α band frontal asymmetry was found frequently.¹³ Also, elevated β power was found in patients with anxiety as well as chronic headaches.^{21,12} The QEEG findings of individuals diagnosed with attention deficit hyperactivity disorder and autistic spectrum disorder were described in detail by other authors.^{14,22-26}

Recently, in the Florida court system, QEEG/electrical neuroimaging testimony, describing temporal abnormalities,

was accepted as valid evidence in a death penalty case, based on Frye criteria.²⁷

Based on the data in this article, formal QEEG training during neurology residency is highly recommended, in order to increase familiarity of young neurologists with this test.

In conclusion, QEEG also served as a starting point and guidance for neurofeedback therapy of selected patients, who decided to elect this modality for their further treatment. The result of neurofeedback treatment will be presented in a separate report.

Declaration of Conflicting Interests

The author(s) declared no potential conflicts of interest with respect to the research, authorship, and/or publication of this article.

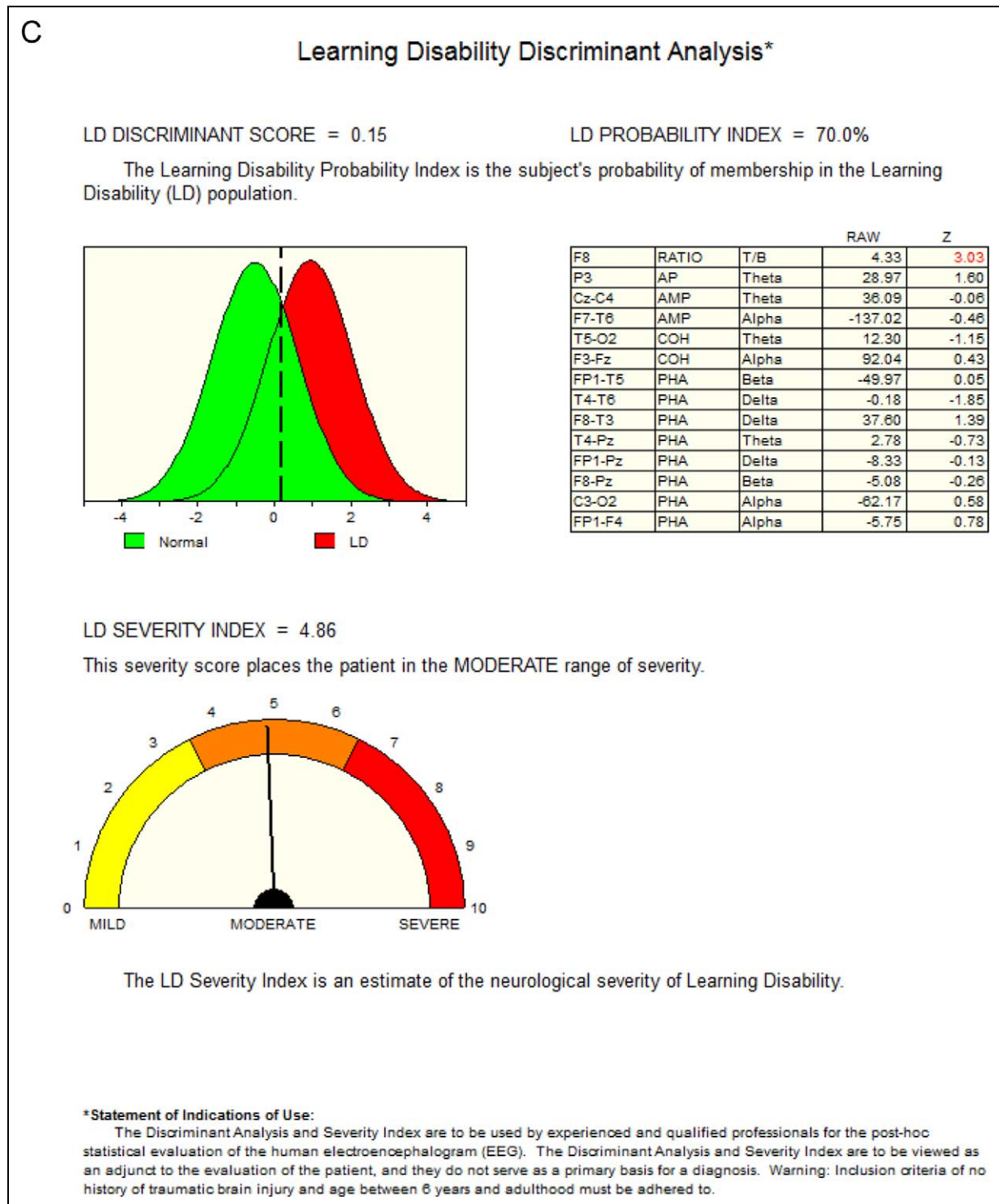


Figure 5. A, Patient with attention deficit disorder (ADD)/Asperger syndrome (AS) showed increased frontotemporal θ power (yellow areas 1-2 standard deviation [SD]; red 2-3 SD). B, Patient with diagnosis of ADD/AS showed increased θ/β ratio (yellow areas 1-2 SD; red areas 2-3 SD). C, Patient with ADD/AS showed positive evidence of learning disability.

Funding

The author(s) received no financial support for the research, authorship, and/or publication of this article.

References

- Michel CM, Koenig T, Brandeis D, Gianotti LR, Waxkerman J. *Electrical Neuroimaging*. New York, NY: Cambridge University Press; 2009.
- Newer MR, Hovda DA, Schrader LM, Vespa PM. Routine and quantitative EEG in mild traumatic brain injury. *Clin Neurophysiol*. 2005;116(9):201-225.
- Aminoff MJ. *Electrodiagnosis in Clinical Neurology*. Philadelphia, PA: Churchill Livingstone; 1999.
- Rizzo M, Eslinger PJ. *Behavioral Neurology and Neuropsychology*. Philadelphia, PA: Saunders; 2004.
- Naunheim RS, Treaster M, English J, Casner T, Chabot R. Use of brain electrical activity to quantify traumatic brain injury in the emergency department [published online August 19, 2010]. *Brain Inj*. 2010.
- NeuroTrax Corporation, Fresh Meadows, NY 11365 (Mindstreams assessment).
- Neuroguide Software, 2001. Applied Neuroscience, Inc. St. Petersburg, FL 33708.
- Thatcher RW, North DM, Curtin RT, et al. An EEG severity index of traumatic brain injury. *J Neuropsychiatry Clin Neurosci*. 2001;13(1):77-87.
- Thatcher RW, North D, Biver C. EEG discriminant analysis of children with learning disabilities: correlations to school achievement and neuropsychological performance. July 31, 2002. Personal communication.
- Pascual-Marqui RD, Michel CM, Lehmann D. Low resolution electromagnetic tomography: a new method for localizing electrical activity in the brain. *Int J Psychophysiol*. 1994;18(1):49-65.
- Pascual-Marqui RD. Review of Methods for Solving the EEG Inverse Problem. *Int J Bioelectromagnetism*. 1999;1(1):75-86.
- Walker JE. QEEG-guided neurofeedback for recurrent migraine headaches. *J Clin EEG Neurosci*. 2011;42(1):59-61.
- Seagrave RA, Cooper NR, Thomson RH, Croft RJ, Sheppard DM, Fitzgerald PB. Individualized alpha activity and frontal asymmetry in major depression. *J Clin EEG Neurosci*. 2011;42(1):45-52.
- Coben R, Clarke AR, Hudspeth W, Barry RJ. EEG power and coherence in autistic spectrum disorder. *Clin Neurophysiol*. 2008;119(5):1002-1009.
- Hargrove JB, Bennett RM, Simons DG, Smith SJ, Nagpal S, Deering DE. Quantitative electroencephalographic abnormalities in fibromyalgia patients. *Clin EEG Neurosci*. 2010;41(3):132-139.
- Coburn KL, Lauterbach EC, Boutros NN, Black KJ, Arciniegas DB, Coffey CE. The value of quantitative electroencephalography in clinical psychiatry: a report by the committee on research of the American Neuropsychiatric Association. *J Neuropsychiatry Clin Neurosci*. 2006;18(4):460-500.
- Clark CR, Gallently CA, Ash DJ, Moores KA, Penrose RA, McFarlane AC. Evidence-based medicine evaluation of electrophysiological studies of the anxiety disorders. *J Clin EEG Neurosci*. 2009;40(2):84-112.
- Duff J. The usefulness of quantitative EEG (QEEG) and neurotherapy in the assessment and treatment of post-concussion syndrome. *Clin EEG Neurosci*. 2004;35(4):198-209.
- Naunheim RS, Treaster M, English J, Casner T, Chabot R. Use of brain electrical activity to quantify traumatic brain injury in the emergency department. *Brain Inj*. 2010;24(11):1324-1329.
- Deslandes A, Veiga H, Cagy M, Fiszman A, Piedade R, Ribeiro P. Quantitative electroencephalography (QEEG) to discriminate primary degenerative dementia from major depressive disorder (depression). *Arq Neuropsiquiatr*. 2004;62(1):44-50.
- Budzynski TH, Budzynski HK, Evans JR, Abarbanel A. *Introduction to Quantitative EEG and Neurofeedback*. Academic Press, imprint of Elsevier, 30 Corporate Drive, Suite 400, Burlington, MA 01803, USA; 2009.
- Fonseca LC, Tedrus GM, Morales C, Vincente Machado A, Almeida MP, Oliveira DO. Epileptiform abnormalities and QEEG in children with attention-deficit/hyperactivity disorder. *Arq Neuropsiquiatr*. 2008;66(3A):462-467.
- Arns M, Gunkelman J, Marinus B, Desiree S. EEG phenotypes predict treatment outcome to stimulants in children with ADHD. *J Integr Neurosci*. 2008;7(3):421-438.
- Di Michele F, Prichep L, John ER, Chabot RJ. The neurophysiology of attention-deficit/hyperactivity disorder. *Int J Psychophysiol*. 2005;58(1):81-93.
- Lansbergen MM, Arns M, Van Dongen-Boomsma M, Spronk D, Buitelaar JK. The increase in theta/beta ratio on resting-state EEG in boys with attention-deficit/hyperactivity disorder is mediated by slow alpha peak frequency. *Prog Neuropsychopharmacol Biol Psychiatry*. 2011;35(1):47-52.
- Pop-Jordanova N, Zorcec T, Demerdzieva A, Gucev Z. QEEG characteristics and spectrum weighted frequency for children diagnosed as autistic spectrum disorder. *Nonlinear Biomed Phys*. 2010;4(1):4.
- State of Florida v. Grady Nelson, case No. F05-00846, 11th Judicial Circuit Court, Miami-Dade County, Florida. QEEG admitted in the penalty phase after Frye Hearing. October 22, 2010.

Reproduced with permission of the copyright owner. Further reproduction prohibited without permission.